

New “seeing” stylet-scope and method for the management of the difficult airway

ALAN H. SHIKANI, MD, FACS, Baltimore, Maryland

Management of the difficult airway is the fundamental responsibility of anesthesiologists, who have developed practice guidelines and algorithms to avoid adverse outcomes.^{1,2} When repeated attempts at securing the airway fail, the help of otolaryngologists is occasionally requested either to assist in the fiberoptic intubation or to perform a surgical opening into the trachea. Definitions of difficult intubation have included failure to intubate, more than 2 laryngoscopies, more than 3 attempts, or longer than 10 minutes trying to pass an endotracheal tube.³ Tracheal intubation fails in approximately 1 in every 2230 nonobstetric patients and 1 in 238 obstetric patients.⁴ Inability to maintain a patent airway may result in aspiration, hypoventilation, hypoxemia, brain damage, or even death. Up to 30% of all deaths attributable to anesthesia are related to difficult airway management, and more than 85% of all respiratory-related, closed malpractice claims involve a brain-damaged or a dead patient.^{5,6} The greater the difficulty in obtaining a patent airway, the greater the trend to use physical force and risk complications, which include direct trauma including broken teeth, hemorrhage, laceration, perforation with subsequent emphysema, and pneumothorax; infection; arytenoid subluxation; or fracture-subluxation of the cervical spine.

Several anatomic and clinical criteria can be assessed in patients to predict difficult tracheal intubation, including mouth opening, Mallampati classification, head and neck movement, ability to project the lower jaw, ability to visualize the hypopharynx, thyromental distance, body weight, and previous history of difficult intubation.^{2,7-10} Laryngoscopic visualization of the hypopharynx has been classified by Cormack and Lehane¹¹ into 4 grades, and there is a direct correlation between the grade of visualization and the difficulty in intubation.² Grades III and IV occur in between 0.3%

and 13% of laryngoscopies and are associated with the more difficult intubations.^{12,13}

A new intubating stylet that offers the ability to visualize the airway is described. Similarly to the classic stylet currently used to assist in intubation, it is inserted into the endotracheal tube and maintains a chosen shape, usually that of a hockey stick, but in addition, it has a lens at the distal end and a fiberoptic cable inside, which is connected to a camera and a video monitor. Whereas intubation with the classic stylet may be a blind or semiblind technique, the “seeing” stylet allows continuous monitoring of the hypopharynx and the airway during introduction of the tube into the glottis.

This new device allows the introduction of a new technique for intubation. With this technique, the mandible is lifted with the left hand and displaced anteriorly until the lower teeth are anterior to the upper teeth while the glottis is continuously visualized on a monitor with the help of the seeing stylet and the endotracheal tube driven into the trachea, without the need of a Macintosh or Miller laryngoscope blade to retract the base of the tongue.

METHODS

Intubating stylet

The new stylet-scope is a complete endoscope consisting of an image fiber bundle, a distal lens, a proximal image fiber connector, several illumination fibers, a proximal illumination connector, and an outer body (Figs 1 and 2). The outer body consists of a malleable stainless-steel sheath selected to have the approximate characteristics of the classic stylet now cur-




Fig 1. Stylet-scope, camera, and illumination connector.

From the Department of Otolaryngology–Head and Neck Surgery, The Johns Hopkins Medical Institutions.

Reprint requests: Alan H. Shikani MD, FACS, Chief, Division of Otolaryngology–Head and Neck Surgery, The Good Samaritan Hospital, 5601 Loch Raven Blvd, Baltimore, MD 21239.

Otolaryngol Head Neck Surg 1999;120:113-6.

Copyright © 1999 by the American Academy of Otolaryngology–Head and Neck Surgery Foundation, Inc.

0194-5998/99/\$8.00 + 0 23/75/91547

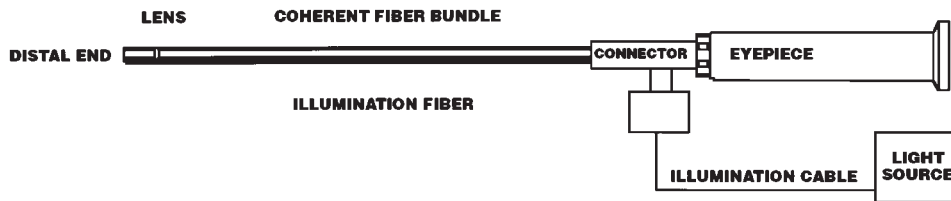


Fig 2. Diagram of stylet-scope.

rently in use. The proximal body is a polymer with encapsulated metal braid to add strength and crush resistance while preserving flexibility. The fiberoptic bundle contains thousands of individual strands of glass that are maintained in a coherent pattern. Each glass strand is about 4 μm in diameter and transmits 1 picture element (pixel) of light. Current technology allows high-quality fibers with 3000, 6000, 10,000, 30,000, and 50,000 pixels. As the pixel count goes up, the relative optimal performance increases, but so do size and rigidity. A 30,000 pixel endoscope was chosen because it provides excellent optical performance while preserving adequate size and flexibility. A 1-piece gradient reflective index lens was used with a suitable focal range and angle, which are fixed and determined at manufacturing but can be customized. The image connector can be connected to all video systems, including small portable video monitors, or to an eyepiece for direct viewing through a reusable optical coupler. An illumination fiber is used to illuminate the targeted body cavity, and the illumination connector is a standard ACMI. The entire stylet-scope is sealed and immersible and can be sterilized with ethylene oxide (Steris Corp, Erie, PA) or it may be soaked in a high-level disinfectant such as glutaraldehyde. The stylet-scope fits in adult and pediatric endotracheal tubes, including sizes 3.0 mm and up. The device is manufactured by Clarus Medical Systems Inc (Golden Valley, MN).

Technique

The stylet is lightly lubricated with a silicone spray and advanced into the tube without its tip protruding past the end of the tube. A few drops of an antifogging agent are placed on the lens. After the usual induction sequence and preoxygenation through adequate mask ventilation, the head is placed in the sniff position to remove the tongue from the posterior pharyngeal wall, and the operator grasps the mandible with the left hand and lifts the jaw. The mandible is then displaced anteriorly until the lower teeth are anterior to the upper teeth. The tip of the tongue may be grasped with a piece of gauze and fully withdrawn out of the mouth, which further clears the airway. Secretions are suctioned; the seeing stylet, preloaded with the endotracheal tube, is inserted into the mouth with the right hand and advanced into the larynx. Successful entry into the trachea is confirmed by direct visualization (Fig 3). In

some patients, it may be necessary to apply pressure to the cricoid cartilage to improve the view of the glottis. The stylet is then removed, the endotracheal tube is connected to the ventilator, and proper intubation is reconfirmed by conventional capnography and auscultation.

Study Protocol

The study protocol was approved by our institutional review board. After giving informed consent, 120 patients (74 children and 46 adults) who were scheduled to undergo routine otolaryngologic procedures were included in this prospective study. The ages of the patients ranged from 2.2 to 73 years (mean of 29 years). There were 71 male and 49 female patients.

RESULTS

Using the Cormack and Lehane classification,¹¹ I assessed most patients as having grades I and II airways (94 and 19, respectively); 6 had grade III airways, and 1 a grade IV airway. Using the seeing stylet, I successfully intubated all patients without complications. After an initial learning period, which was relatively brief, manipulation of the stylet-endotracheal tube as 1 unit became easier; 106 patients were successfully intubated with the first attempt, 11 after 2 attempts, and 3 after 3 attempts. The patients who presented difficulty were the ones with grades III and IV airways, in whom intubation would be expected to be difficult with any method. Cricoid pressure was performed in 21 patients to improve visualization of the glottis. In all children and most adults, the airways could be clearly visualized with the stylet, with no need for a laryngoscope blade for exposure. In 4 adult patients with grade II airways and in 5 patients with grades III and IV airways, a Macintosh laryngoscope blade was also used to further retract the base of the tongue, and in those cases, the seeing stylet was particularly helpful in maneuvering around the epiglottis and entering the glottis under direct vision. In these 9 relatively difficult airways, the blade combined with the seeing stylet was superior to the blade alone or the stylet alone. The improved visualization minimized the need to press on the teeth with the blade and lessened the risk of trauma to the denti-

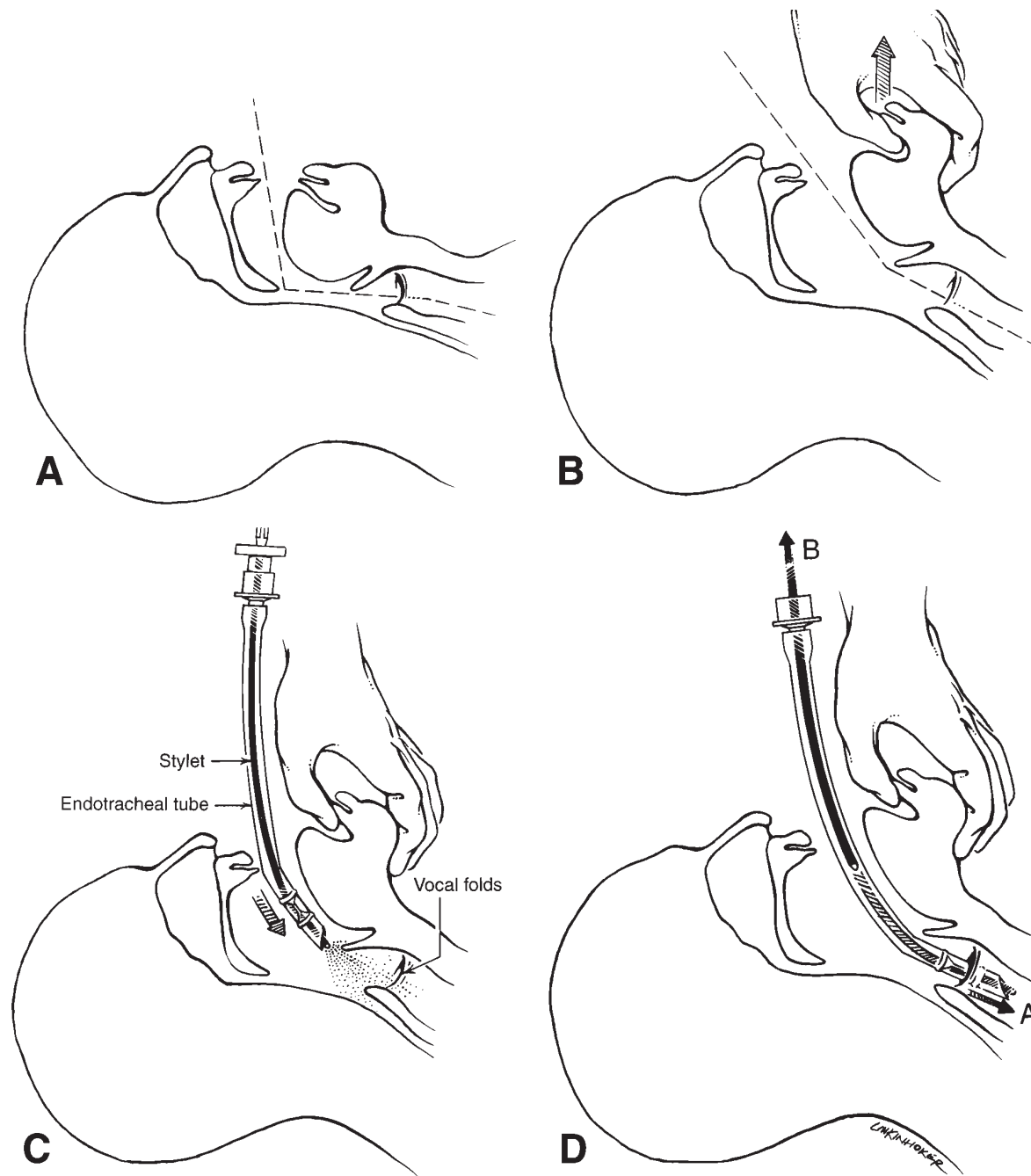


Fig 3. Technique of intubation with the stylet-scope. **A**, Head is initially in the resting position. **B**, Head is placed in the sniff position, and mandible is lifted with the left hand. **C**, Stylet, preloaded with the endotracheal tube, is inserted into the mouth with the right hand, and the larynx is visualized. **D**, Stylet-endotracheal tube unit is advanced through the vocal cords (**A**) under direct visualization, and the stylet is removed (**B**).

tion, hypopharynx, and larynx. Bloody airways were not a problem in any of the patients. In the 5 patients who underwent awake intubation, discomfort was minimized because there was no need to retract the base of the tongue with a blade.

DISCUSSION

Successful management of a difficult airway begins with recognition of the potential problem through appropriate preoperative assessment. If there is a good possibility that intubation and/or ventilation by mask

will be difficult, the intubation should be attempted with the patient awake, classically with the use of a fiberoptic scope.^{1,13-15} The more challenging situation occurs when the difficult airway is confronted unexpectedly. If the patient is already anesthetized and/or paralyzed and intubation is found to be difficult, physical force and many repeated attempts at intubation should be avoided because of the increased risk of complications. The new seeing stylet combines the advantages of a fiberoptic scope and the semirigidity of a classic metal stylet, which provides the anesthesiologist the versatility of using it in patients who are fully awake or already asleep. Its advantage over the flexible fiberoptic scope is that it can keep its semirigid shape, allowing better maneuverability around a large epiglottis that is flopping against the posterior pharyngeal wall, which in the supine position, may constitute an insurmountable problem using a flexible scope. This rigidity may be the main advantage of this device. In addition, it offers the advantages of the light wand, which has shown a lower incidence of postoperative sore throat, hoarseness and dysphagia,¹⁶ but it is superior to the light wand in that it not only acts as a source of illumination but also allows visualization and helps direct the course of the endotracheal tube. In patients with head and neck trauma, such as cervical spine injury where neck extension should be avoided, or LeFort fractures where jaw mobility is limited, intubation may be significantly facilitated. Management of the difficult pediatric airway may also be improved, for example, in newborns who have a dramatically different anatomy and more delicate laryngeal structures than adults and in children with congenital syndromes with mandibulofacial dysostosis, micrognathia, Treacher Collins syndrome, and so forth. Other situations that also may be helped include head and neck tumors, infections that compromise the airway such as epiglottitis, Ludwig's angina, Quincy and retropharyngeal abscesses, heavy body weight in cases of pregnancy or morbid obesity, and skeletal axis conditions such as rheumatoid arthritis, scoliosis, and kyphosis. The stylet may also be helpful in recognizing accidental esophageal intubation and assisting in correct placement of a laryngeal mask airway. Finally, as the stylet is attached to a video monitor, the instruction of anesthesia residents in management of the difficult airway management may be enhanced. Because difficult situations occur infrequently, practical teaching has been sporadic, and more experienced staff tend to handle difficult cases themselves, which has limited resident

teaching. The Council for Graduate Medical Education requires "significant experience with certain specialized techniques," which include but are not limited to fiberoptic intubations.¹⁷ With such a wide range of applications, the seeing stylet promises to be a valuable addition to the armamentarium of the anesthesiologist.

In conclusion, this study describes a new intubating stylet that has a lens at the distal end, has a fiberoptic cable inside, and is connected to a camera and a video monitor, thereby allowing continuous visualization of the airway during introduction of the tube into the glottis. The stylet facilitates the management of the difficult airway, minimizes the risk of trauma to the glottis or dentition, and allows intubation without the need of the rigid laryngoscope blade to retract the base of the tongue.

REFERENCES

1. Practice guidelines for management of the difficult airway. A report by the American Society of Anesthesiologists Task Force on Management of the Difficult Airway. *Anesthesia* 1993;78:597-602.
2. Benumof JL. Management of the difficult airway, with special emphasis on awake tracheal intubation. *Anesthesiology* 1991;75:1087-110.
3. Rose KD, Cohen M. The airway: problems and predictions in 18,500 patients. *Can J Anaesth* 1994;41:371-83.
4. Samson GLT, Young JRB. Difficult airway intubation: a retrospective study. *Anesthesia* 1987;42:487-90.
5. Caplan RA, Posner KL, Ward RJ, et al. Adverse respiratory events in anesthesia: a closed claims analysis. *Anesthesiology* 1990;72:828-33.
6. Gibbs CP. Gastric aspiration: prevention and treatment. *Clin Anesthesiol* 1986;4:47-52.
7. Williamson JA, Webb RK, Szekely S, et al. Difficult intubation: an analysis of 2000 incident reports. *Anaesth Intensive Care* 1993;21:602-7.
8. Mallampati SR, Gatt SP, Gugino LD, et al. A clinical sign to predict difficult tracheal intubation: a prospective study. *Can J Anaesth* 1985;32:429-34.
9. Nichol HL, Zuck B. Difficult laryngoscopy: the "anterior" larynx and the atlanto-occipital joint. *Br J Anaesth* 1983;55:141-4.
10. Wilson ME, Spiegelhalter D, Robertson J, et al. Predicting difficult intubation. *Br J Anaesth* 1988;61:211-6.
11. Cormack RS, Lehane J. Difficult tracheal intubation in obstetrics. *Anesthesia* 1984;39:1105-11.
12. Williams KN, Carli F, Cormack RS. Unexpected difficult laryngoscopy: a prospective survey in routine general anesthesia. *Br J Anesth* 1991;66:38-44.
13. Frerk CM. Predicting difficult intubation. *Anesthesia* 1991;46:1005-8.
14. Schwartz DE, Wiener-Kronish JP. Management of the difficult airway. *Clin Chest Med* 1991;12:483-95.
15. Norton ML, Brown AC. Difficult airway clinic. *Otolaryngol Clin North Am* 1990;23:771-85.
16. Friedman PG, Rosenberg MK, Lebendom-Mansour M. A comparison of light wand and suspension laryngoscopic intubation techniques in outpatients. *Anesth Analg* 1997;85:578-82.
17. Koppel JN, Reed AP. Formal instruction in difficult airway management. A survey of anesthesiology residency programs. *Anesthesiology* 1995;83:1343-6.